

INFECTION AND SYSTEMIC COMPLICATIONS BY PASTEURELLA SPP. IN A RABBIT: A CASE STUDY

INFECÇÃO E COMPLICAÇÕES SISTÊMICAS POR PASTEURELLA SPP. EM COELHO: ESTUDO DE CASO

Thayssa Duarte Costa¹

Juliana Lyra Timoteo²

Fernanda Senter Magajevski³

Jaqueline Assumpção Diniz⁴

ABSTRACT: The coexistence of rabbits in parks and public recreation areas is a common scene; however, this interaction is not without risks as rabbits can be carriers of bacterial infectious diseases, posing a potential risk to public health. The *Pasteurella* genus, including *Pasteurella multocida*, plays a central role in developing bacterial infections that affect rabbits and other lagomorphs. Infection by this genus typically manifests with respiratory symptoms such as nasal discharge and sneezing, but the concern goes beyond that due to its zoonotic nature. These pathogens have the ability to be transmitted to humans, usually through bites, scratches, or direct contact, emphasizing the importance of careful management and preventive measures. Diagnosis in rabbits involves a comprehensive analysis, including clinical signs, medical history, laboratory tests, and specific tests. Symptoms such as nasal discharge, watery eyes, abscesses, and lethargy are common. Medical history and physical examination are crucial, along with the culture of samples and, when possible, serological tests. This case report describes the occurrence of pasteurellosis in a female rabbit treated at CRAS - Pró Arara "Raul de Barros Winter" in Araras, São Paulo, Brazil, highlighting the importance of surveillance, proper management, and awareness to mitigate public health risks associated with the coexistence of rabbits and humans in public recreation areas.

2591

Keywords: Animal welfare. Bacteriosis. Cranial deformation. Respiratory illness.

RESUMO: O convívio de coelhos em parques e áreas públicas de recreação é uma cena comum, no entanto, essa interação não está isenta de riscos, pois coelhos podem ser portadores de doenças infecciosas bacterianas, representando um potencial risco para a saúde pública. O gênero *Pasteurella*, incluindo a *Pasteurella multocida*, desempenha um papel central nas infecções bacterianas que afetam coelhos e outros lagomorfos. A infecção por esse gênero geralmente se manifesta com sintomas respiratórios, como corrimento nasal e espirros, mas a preocupação vai além disso, devido à sua natureza zoonótica. Esses patógenos têm a capacidade de serem transmitidos a seres humanos, geralmente por mordidas, arranhões ou contato direto, enfatizando a importância do manejo cuidadoso e medidas de prevenção. O diagnóstico em coelhos envolve uma análise abrangente, incluindo sinais clínicos, histórico médico, exames laboratoriais e testes específicos. Sintomas como corrimento nasal, olhos lacrimejantes, abscessos e letargia são comuns. O histórico médico e exame físico são cruciais, juntamente com a cultura de amostras e, quando possível, testes sorológicos. Este relato de caso descreve a ocorrência de pasteurelose em uma coelha atendida no CRAS - Pró Arara "Raul de Barros Winter" de Araras, São Paulo, Brasil, destacando a importância da vigilância, manejo adequado e conscientização para mitigar os riscos à saúde pública associados à convivência entre coelhos e seres humanos em locais públicos de recreação.

Palavras-chave: Bem-estar animal. Bacteriose. Deformação craniana. Enfermidade respiratória.

¹Centro Universitário Anhanguera – UNIFIAN, Leme, São Paulo; Doutora em Zootecnia e Docente do curso de Medicina Veterinária.

²Centro Universitário Anhanguera – UNIFIAN, Leme, São Paulo; Graduanda em Medicina Veterinária.

³Centro de Reabilitação de Animais Silvestres – CRAS, Araras, São Paulo; Doutora em Medicina Veterinária.

⁴Centro de Reabilitação de Animais Silvestres – CRAS, Araras, São Paulo; Doutora em Medicina Veterinária.

INTRODUCTION

The presence of rabbits in parks and public recreation areas is a common sight in urban areas. However, while they can add charm and interest to these spaces, it is important to recognize the potential risk that this coexistence can bring (MACHADO, 2015; VALENTIM et al., 2018). Rabbits are susceptible to bacterial diseases, and due to their close contact with the environment and other animal species, both wild and domesticated rabbits inhabiting such areas can become carriers of pathogens that may be transmitted to the human population frequenting these spaces (FERREIRA et al., 2016). Therefore, it is essential for park management authorities to adopt measures of surveillance, management, and awareness to mitigate the public health risks associated with the interaction between rabbits and visitors to these locations.

Bacterial infectious diseases pose a dual concern when it comes to rabbits, whether they are wild or domestic, due to their zoonotic potential (HILL; BROWN, 2011). Wild rabbits are susceptible to a variety of bacterial pathogens that can be transmitted to humans through direct or indirect contact (MASSACCI et al., 2018). Pasteurellosis, caused by bacteria of the *Pasteurella* genus, and tularemia, associated with *Francisella tularensis*, are among the bacterial diseases that can affect wild rabbits and, at the same time, represent a risk of infection for people who come into contact with these animals or their habitats (CARVALHO, 2012; SANTIANI et al., 2019). Domestic rabbits, on the other hand, can carry bacteria like *Pasteurella multocida*, which not only impact their own health but can also be transmitted to their caregivers (ZHU et al., 2020).

The *Pasteurella* genus comprises a variety of gram-negative bacteria that play a central role in bacterial infections affecting rabbits and other members of the lagomorph family (DEEB; DIGIACOMO, 2000). Particularly highlighted is *Pasteurella multocida*, which can colonize the respiratory tract of these animals, leading to a range of symptoms that vary from nasal discharge and sneezing to the formation of abscesses and conjunctivitis (FERREIRA et al., 2016). The peculiarity of these *Pasteurella* spp. infections is their potential tendency to manifest as respiratory diseases. However, beyond this concern, it is of utmost importance to emphasize the zoonotic nature of these pathogens (HILL; BROWN, 2011; WILSON; HO, 2013). They have the ability to be transmitted to humans, typically through bites, scratches, or direct contact, highlighting the importance of careful management and the adoption of preventive measures to protect both the health of the animals and that of the people who interact with them (HILL; BROWN, 2011).

The diagnosis of *Pasteurella* spp. in rabbits typically involves a combination of clinical signs, the animal's medical history, laboratory tests, and specific tests (WANG et al., 2019). Common symptoms include nasal discharge, sneezing, watery eyes, abscesses in the neck and head region, loss of appetite, lethargy, and difficulty breathing (SPILKI, 2002); the rabbit's medical history is crucial for understanding the progression of symptoms, environmental exposures, and other health conditions that may contribute to the infection (FERREIRA et al., 2016); in addition to a detailed physical examination, culturing samples of nasal secretions, abscesses, or other materials can be performed to isolate and identify the bacteria causing the infection, providing greater diagnostic accuracy (ESPINOSA et al., 2020); finally, if possible, serological tests are recommended that can help detect the presence of antibodies against *Pasteurella* in the patient's blood (D'AMICO et al., 2022).

This study reports the occurrence of pasteurellosis in a rabbit from CRAS - Araras, São Paulo, Brazil.

MATERIAL AND METHODS

On June 30, 2023, a New Zealand breed female rabbit with white fur and brown spots, originating from the Fabio Da Silva Prado Municipal Park - Municipal Lake, located in the city of Araras, São Paulo, Brazil, was admitted to CRAS - Pró Arara "Raul de Barros Winter" presenting symptoms that included severe dyspnea, sneezing, and a considerable amount of mucopurulent discharge throughout the nasal region, causing complete obstruction of the airways, as well as discharge and tearing in the eyes (Figure 1). It was reported that the rabbit shared the environment with another of its kind, as well as chickens and a guinea pig in an enclosure with concrete and packed earth. The animals were fed donated pellets and corn, and they rarely consumed green leaves. Local hygiene occurred every two days by a non-specific caregiver.

The initial approach involved sedation, with the administration of 0.4 ml of Zoletil®. Thorough cleaning of the nose, eyes, and anal area was performed. An intramuscular administration of 0.3 ml of enrofloxacin (1/14), 0.4 ml of dexamethasone, and 0.3 ml of meloxicam was given. Additionally, an oral probiotic supplement from Ouro Fino Biocanis® was administered (1/14). During auscultation, pronounced noises and continuous discharge were noticed. To alleviate these symptoms, 0.3 ml of atropine was administered, and inhalation with 3 ml of saline solution and 0.5 ml of dexamethasone was performed. The animal was exposed to

oxygen for 10 minutes at a rate of 2 liters per minute and then at 4 liters per minute. Additionally, 5 drops of Lacribell® were applied to each eye, which acts to lubricate the eyes and temporarily relieve irritation and burning, followed by the administration of 1 drop of Cyclocort® Colírio in each eye, indicated for the treatment of eye infections caused by susceptible microorganisms. Throughout all days, constant cleaning of the nostrils and eyes was maintained to ensure hygiene and minimize discharge. This comprehensive approach aimed to treat the evident symptoms, promote the comfort of the rabbit, and improve its overall condition.

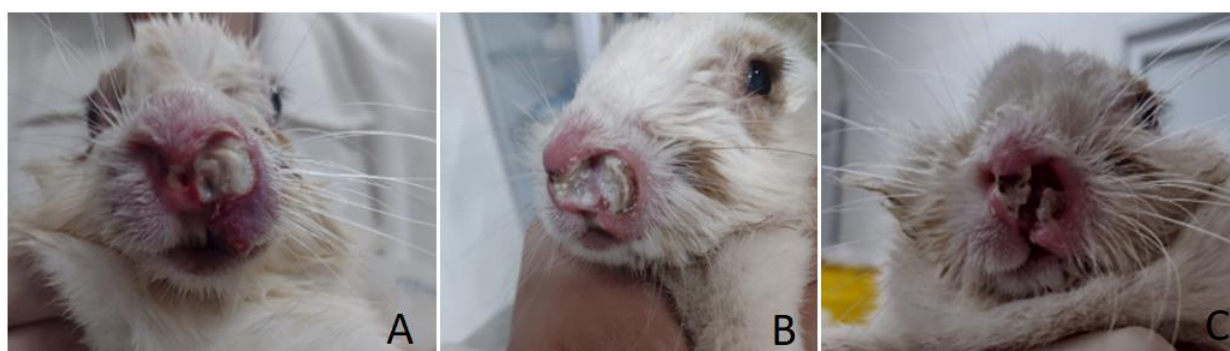
During one week, the animal's weight loss was observed (from 2.290 kg to 2.255 kg) despite being fed fresh cabbage and pellets. A dose of 0.3 ml of enrofloxacin (6/14) was administered, followed by 0.4 ml of dexamethasone and 0.4 ml of ketoprofen, in addition to the probiotic administration. To treat the persistent respiratory symptoms, inhalation with 3 ml of saline solution and 1.5 ml of acetylcysteine was performed to combat the underlying infection and provide relief from the symptoms in an attempt to improve the overall well-being of the rabbit (Figure 1).

Five days after the previous treatment, there was still weight loss, decreasing from 2.255 kg to 2.045 kg. Despite continuous efforts to maintain cleanliness in the nasal region, there was no improvement, and mucopurulent discharge was still present, making breathing difficult. During this period, the rabbit's diet included a porridge composed of half a portion of banana, a complete nutritional supplement that helps normalize digestion in critical cases, Oxbow Critical Care®, and Mucilon®, as part of supportive care for its recovery. 2594

After another five days of treatment, the animal began to show lethargy and a continuous decrease in weight, with its weight dropping from 2.045 kg to 1.915 kg, and there were no signs of a decrease in the amount of discharge. Additionally, the rabbit's fur remained ruffled. The treatment plan was adjusted, including the administration of 0.3 ml of enrofloxacin (15/14), 0.5 ml of ketoprofen, and 0.2 ml of dexamethasone. In an attempt to provide nutritional support and combat lethargy, the rabbit was fed the previous diet supplemented with the vitamin supplement Glicopan Pet®. It was also observed that the animal appeared to be choking, leading to inhalation with 3 ml of saline solution, 1.5 ml of acetylcysteine, and 1 ml of dexamethasone.

Figure 1. A - A rabbit from Fabio Da Silva Prado Municipal Park - Municipal Lake, located in the city of Araras, São Paulo, Brazil, admitted to CRAS - Pró Arara "Raul de Barros Winter," presenting severe symptoms of dyspnea and a considerable amount of mucopurulent discharge throughout the nasal region, as well as discharge and tearing in the eyes. B - The

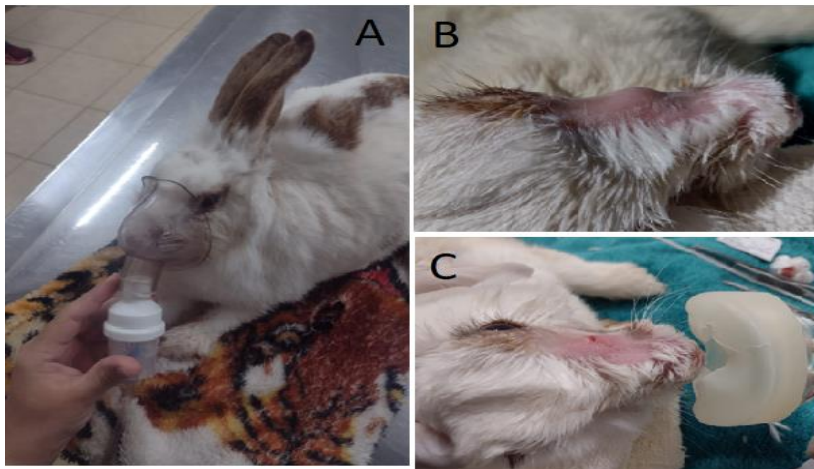
animal on the fifth day of treatment, with meticulous cleaning of the nose, eyes, and anal area. The rabbit was receiving antibiotics from the fluoroquinolone class (enrofloxacin), corticosteroids (dexamethasone), and a non-steroidal anti-inflammatory medication (meloxicam), in addition to a probiotic supplement. During auscultation, pronounced noises and continuous discharge were noticed, so in addition to the previous medication, the rabbit was also exposed to oxygen. C - At the end of the first week of treatment, there was no improvement in the nasal region, and weight loss was still observed. During this period, a fruit porridge with nutritional supplementation was included in the diet as part of supportive care for recovery.



Two days after this treatment, the rabbit showed no interest in the fruit porridge but consumed cabbage. It was then administered 100 ml of subcutaneous lactated Ringer's solution, and its weight on that date was recorded as 2.120 kg. Two days later, there was a reduction in the rabbit's body weight, recorded at 1.845 kg. On this day, it received another 100 ml of subcutaneous lactated Ringer's solution and showed slight interest in pellets. In the following days, observing the apathy and increased mucopurulent discharge, antibiotic treatment was resumed, with the administration of 0.2 ml of enrofloxacin (1/10) and 0.2 ml of meloxicam (1/3), along with the probiotic. The rabbit also consumed cabbage and continued to receive the subcutaneous lactated Ringer's solution, now supplemented with 2 ml of glucose. 2595

At the end of July, the rabbit's weight was recorded at 1.850 kg, and the presence of hematochezia (bloody stool) was observed, along with myiasis in the vaginal area, which required urgent cleaning procedures. For nutrition, the rabbit was given banana, Oxbow Critical Care®, Organew Pet®, and Glicopan Pet®. In addition, the rabbit underwent inhalation with 4.5 ml of saline solution and 1 ml of dexamethasone, BID (twice a day). It was also administered 0.2 ml of enrofloxacin (05/15), 0.06 ml of furosemide subcutaneously, and 0.02 ml of ivermectin subcutaneously (Figure 2).

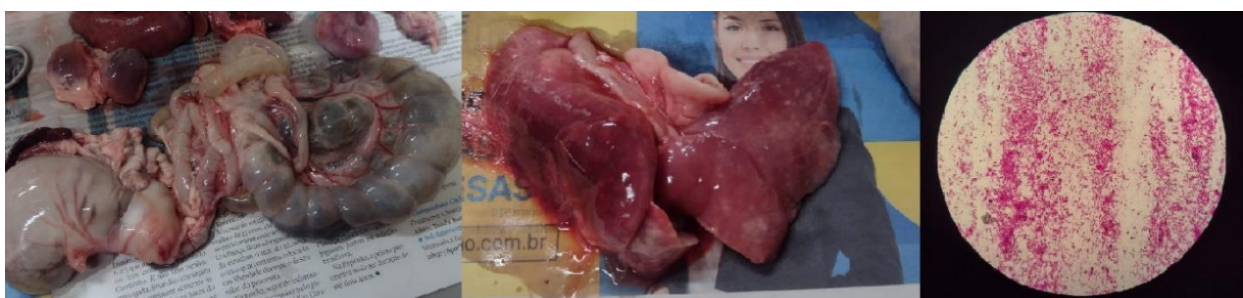Figure 2. A - Inhalation procedure aimed at the animal's comfort. B - Abscess in the rabbit's nostril. C - Post-lancing and local drainage procedure, resulting in the elimination of a considerable amount of mucopurulent discharge.



The rabbit continued to show a lack of appetite, necessitating the provision of fruit porridge to meet its nutritional needs. Additionally, the appearance of an abscess in the nostril was observed, leading to sedation with 0.3 ml of Zoletil® for lancing and drainage procedures, resulting in the elimination of a considerable amount of discharge. The rabbit also received 0.2 ml of enrofloxacin (6/15), 0.06 ml of subcutaneous furosemide, 0.2 ml of meloxicam (1/3), oral iron (1/5), and a nutritional supplement. Its weight on that day was recorded as 1.785 kg (Figure 2).

Despite the collection of material for an antibiogram, on June 29, the rabbit passed away, concluding its period of treatment and medical monitoring. Subsequently, a necropsy of the animal was performed, and contents from the abscess in the nasal region were collected for microbiological study, confirming the presence of the *Pasteurella* spp. pathogen (Figure 3).

Figure 3. Sequential images from the necrotic study of the rabbit and Gram stain research of the nasal abscess. In the left image, there is a picture of enteritis, with the presence of intestinal gases and poorly digested material. Next, pulmonary abscesses in both lungs are observed. Finally, confirmation of the pathogen in the mucopurulent material removed from the nasal region.



RESULTS AND DISCUSSION

Observing the rabbit's feeding history, primarily consisting of pellets and corn and limited availability of green leafy vegetables, it may have impacted the rabbit's health and consequently, the resilience of its immune system. Lagomorphs are herbivores that rely on a diet rich in fiber, vitamins (such as vitamin A for eye health, vitamin D for calcium absorption, vitamin E for antioxidant protection, and B-complex vitamins for basal metabolism), and minerals (including calcium, phosphorus, potassium, magnesium, iron, and copper) to maintain a strong immune system and a healthy digestive system. Therefore, the lack of these components can weaken these systems and make them more susceptible to diseases (ALMAMARY et al., 2001; DE OLIVEIRA; PÁDUA, 2010; GOMES et al., 2021), including a predisposition to bacterial infections, such as those caused by *Pasteurella* spp.

Another factor related to the environment was the insufficient frequency of local hygiene, carried out only every two days by a non-specific caregiver, raising concerns about maintaining a healthy environment for the animals. The accumulation of organic material and inadequate cleaning can create a conducive environment for the proliferation of pathogens. Additionally, the coexistence of different animal species in the same shared space increases the potential for disease transmission (COMBES et al., 2017; CHEBET et al., 2018). Therefore, emphasizing the need for rigorous hygiene measures, frequent cleaning of shared areas, and caregiver awareness is crucial. These actions not only protect the health of the animals but also minimize risks to human health, especially when dealing with potentially zoonotic diseases (HUNEAU-SALAÜN et al., 2015; CONRAD et al., 2017).

The initial approach adopted in the treatment of the rabbit was comprehensive and focused on relieving the immediate symptoms of *Pasteurella* spp. infection. Sedation allowed for careful intervention, including thorough cleaning of the nasal, ocular, and anal areas. The use of enrofloxacin, dexamethasone, and meloxicam addressed bacterial infection, inflammation, and provided pain relief, while the probiotic supplement was administered to support gastrointestinal health. The use of fluoroquinolones in lagomorphs can be beneficial in the treatment against pathogens like *Escherichia coli*, *Pseudomonas* spp., and *Pasteurella* spp. However, there are associated risks since rabbits are particularly sensitive to certain drugs in this class, which can lead to severe side effects such as gastrointestinal disorders and joint cartilage lesions (MAH et al., 2007; BLANC et al., 2018). The use of corticosteroids in this species can reduce inflammation and alleviate symptoms of inflammatory conditions such as allergies and

autoimmune diseases, but it also carries risks, including the potential for immune system suppression, increased susceptibility to infections, gastrointestinal disorders, and side effects like increased thirst and urination (RUDZIK et al., 2022; TANNER et al., 2023), which did not occur with the studied rabbit. Additionally, prolonged or high-dose use can result in serious adverse effects such as muscle weakness and skin problems (MOHAMED et al., 2022). Regarding the use of non-steroidal anti-inflammatory drugs (NSAIDs) in lagomorphs, it has been reported for pain relief and inflammation associated with conditions such as arthritis and injuries. This class of medication is aimed at providing temporary relief of symptoms and improving the well-being of animals (JEFFREY et al., 2023).

The auscultation revealed concerning respiratory symptoms, leading to the administration of atropine and inhalation with saline solution and dexamethasone to improve respiratory function. The primary reason for administering atropine to rabbits is to treat respiratory system-related issues, such as bronchoconstriction or excessive secretion, which can occur in conditions like respiratory infections or other diseases affecting the respiratory tract (KOSHIKA et al., 2023). This drug acts as a bronchodilator, relaxing the muscles of the airways and reducing mucus production, which can help improve the breathing of animals with respiratory problems. Atropine can also be used to treat cases of bradycardia (SÁNCHEZ-RÍOS et al., 2022). Dexamethasone, a synthetic corticosteroid, is administered to reduce inflammation and suppress allergic responses, intense inflammations, or autoimmune diseases (BALLA et al., 2022).

2598

However, despite the comprehensive approach, the animal still experienced weight loss over a week. This led to a new intervention, including the use of ketoprofen, as well as a second session of inhalation with acetylcysteine, aimed at combating the underlying infection and relieving persistent respiratory symptoms. Acetylcysteine is a medication that helps thin mucus in the airways and can be useful when there is an excessive production of mucus in the airways. Therefore, inhalation can help loosen the mucus, facilitating its removal from the airways and thus relieving congestion and respiratory problems (SHENG et al., 2022; UYAR, H. G. et al., 2022). In cases of *Pasteurella* spp. infections, where mucopurulent secretion is common, acetylcysteine can be used to make breathing more comfortable for the animal and promote the elimination of purulent material, which is especially important for animals with persistent respiratory symptoms. The use of ketoprofen, also an NSAID, in rabbits may be considered when there is evidence of significant pain or inflammation, especially in situations where

chronic inflammation may be contributing to weight loss and pain relief (SANTANA et al., 2022).

The persistence of *Pasteurella* spp. in rabbits, despite treatment with medications, can be challenging due to the nature of the pathogen and individual animal conditions. This bacterium is known for its ability to form abscesses and hide in tissues, making it difficult to access and completely eliminate with antibiotics (MAHROUS et al., 2022). Furthermore, the development of antibiotic resistance can occur, rendering standard therapies less effective (ABO-EL-SOUD; GOUDAH, 2010). The animal's immune response also plays a crucial role in clearing the infection, and rabbits with weakened immune systems may struggle more to fight off this microorganism (ZHU et al., 2023). The progression of the infection to a systemic problem in this case possibly occurred due to the bacterium's ability to spread throughout the body and cause secondary infections, as the pathogen can lead to a chronic inflammatory response (as observed in the material found in the nasal region and pulmonary auscultation), resulting in damage to organs and tissues (KUBATZKY, 2022; QIU et al., 2022). Another factor that supports this theory is the presence of gases and swelling in the intestinal organs observed during necropsy, suggesting that the infection may have compromised the normal functioning of the gastrointestinal tract, leading to disturbances in intestinal motility, gas accumulation, and possible partial or complete intestinal obstruction (MAHROUS et al., 2022; NABIEVA, 2023). Prolonged inflammation can also result in damage to the intestinal walls, affecting nutrient absorption and leading to symptoms such as diarrhea, weight loss, and abdominal discomfort. The presence of white spots in the lungs, also observed during necropsy, is a common scenario in the formation of lung abscesses that may result from the immune system's response to bacterial infection (OKERMAN et al., 1979; AL-HADDAWI et al., 2001). The white spots represent areas of pus, consisting of white blood cells, dead bacteria, and inflammatory fluid. These lesions can affect lung function and lead to severe respiratory symptoms, as well as serve as a route for dissemination to other body regions.

2599

CONCLUSION

Pasteurella spp. infection can lead to a variety of symptoms and systemic complications. In this study, the infection initially presented with respiratory symptoms such as dyspnea, sneezing, and nasal and ocular discharge. Treatment involved a comprehensive approach, including antibiotics, anti-inflammatories, and supportive therapy. However, throughout the

treatment, the animal continued to experience weight loss and persistent respiratory symptoms, indicating that the bacteria may have caused severe systemic complications. This was further evidenced by the presence of lung and intestinal abscesses observed during the necropsy, suggesting that the infection had spread to internal organs, compromising the animal's health. Ultimately, this case underscores the importance of early surveillance and treatment of *Pasteurella* infections in rabbits. Additionally, it highlights the need for preventive measures such as good hygiene practices and the isolation of sick animals to prevent the spread of the microorganism.

REFERENCES

1. ABO-EL-SOUD, K.; GOUDAH, A. Influence of *Pasteurella multocida* infection on the pharmacokinetic behavior of marbofloxacin after intravenous and intramuscular administrations in rabbits. **Journal of veterinary pharmacology and therapeutics**, v. 33, n. 1, p. 63-68, 2010.
2. AL-HADDAWI, M. H. et al. Ultrastructural pathology of nasal and tracheal mucosa of rabbits experimentally infected with *Pasteurella multocida* serotype D: 1. **Research in veterinary science**, v. 70, n. 3, p. 191-197, 2001.
3. AL-MAMARY, M. et al. In vivo effects of dietary sorghum tannins on rabbit digestive enzymes and mineral absorption. **Nutrition Research**, v. 21, n. 10, p. 1393-1401, 2001. 2600
4. BALLA, A. et al. Understanding dexamethasone kinetics in the rabbit tear fluid: Drug release and clearance from solution, suspension and hydrogel formulations. **European Journal of Pharmaceutics and Biopharmaceutics**, v. 172, p. 53-60, 2022.
5. BLANC, L. et al. High-resolution mapping of fluoroquinolones in TB rabbit lesions reveals specific distribution in immune cell types. **Elife**, v. 7, p. e41115, 2018.
6. CARVALHO, M. O coelho bravo e zoonoses emergentes–Tularémia. In: **IV Congresso da Fauna Selvagem WAVES Portugal: Livro de Resumos**. Instituto Politécnico de Bragança, Escola Superior Agrária, p. 47-47. 2012.
7. CHEBET, J. et al. Prevalence, control and risk factors associated with rabbit mange in Kiambu and Nyeri counties, Kenya. **Livestock Research for Rural Development**, v. 30, n. 6, p. 108, 2018.
8. COMBES, S. et al. Impact of feed restriction and housing hygiene conditions on specific and inflammatory immune response, the cecal bacterial community and the survival of young rabbits. **Animal**, v. 11, n. 5, p. 854-863, 2017.
9. CONRAD, C. C. et al. Farm fairs and petting zoos: a review of animal contact as a source of zoonotic enteric disease. **Foodborne pathogens and disease**, v. 14, n. 2, p. 59-73, 2017.

10. D'AMICO, F. et al. Spreading of *Pasteurella multocida* infection in a pet rabbit breeding and possible implications on healed bunnies. **Veterinary Sciences**, v. 9, n. 6, p. 301, 2022.
11. DE OLIVEIRA, M. C.; PÁDUA, G. T. Restrição alimentar em coelhos em crescimento– Revisão de literatura. **Pubvet**, v. 4, p. Art. 730-737, 2010.
12. DEEB, B. J.; DIGIACOMO, R. E. Respiratory diseases of rabbits. **Veterinary Clinics of North America: Exotic Animal Practice**, v. 3, n. 2, p. 465-480, 2000.
13. ESPINOSA, J. et al. Causes of mortality and disease in rabbits and hares: a retrospective study. **Animals**, v. 10, n. 1, p. 158, 2020.
14. FERREIRA, T. S. P. et al. Pheno-and genotypic characterization of *Pasteurella multocida* isolated from cats, dogs and rabbits from Brazil. **Comparative Immunology, Microbiology and Infectious Diseases**, v. 45, p. 48-52, 2016.
15. GOMES, T. R. et al. Farelo de castanha de caju (*Anacardium occidentale* L.) na alimentação de coelhos em crescimento. **Ciência Animal Brasileira**, v. 21, 2021.
16. HILL, W. A.; BROWN, J. P. Zoonoses of rabbits and rodents. **Veterinary Clinics of North America: Exotic Animal Practice**, v. 14, n. 3, p. 519-531, 2011.
17. HUNEAU-SALAÜN, A. et al. Husbandry factors and health conditions influencing the productivity of French rabbit farms. **World Rabbit Science**, v. 23, n. 1, p. 27-37, 2015.
18. JEFFREY, A. et al. Examination of the pharmacokinetics and differential inhibition of cyclooxygenase isoenzymes in New Zealand white rabbits (*Oryctolagus cuniculus*) by the non-steroidal anti-inflammatory Robenacoxib. **Journal of Veterinary Pharmacology and Therapeutics**, v. 46, n. 2, p. 103-111, 2023.
19. KOSHIKA, K. et al. Involvement of α -and β -Adrenergic Receptors in Skeletal Muscle Blood Flow Changes During Hyper-/Hypocapnia in Anesthetized Rabbits. **Anesthesia Progress**, v. 70, n. 2, p. 58-64, 2023.
20. KUBATZKY, K. F. *Pasteurella multocida* toxin–lessons learned from a mitogenic toxin. **Frontiers in Immunology**, v. 13, p. 1058905, 2022.
21. MACHADO, L. C. Pesquisas de preferência, divulgação da atividade de cunicultura e mercado pet cunicula brasileiro. **Revista brasileira de Cunicultura**, v. 8, p. 1-12, 2015.
22. MAH, F. S. et al. Zymar (Gatifloxacin 0.3%) shows excellent Gram-negative activity against *Serratia marcescens* and *Pseudomonas aeruginosa* in a New Zealand White rabbit keratitis model. **Cornea**, v. 26, n. 5, p. 585-588, 2007.
23. MAHROUS, E. H. et al. Molecular detection and characterization of *Pasteurella multocida* isolated from rabbits. **J. Anim. Health Prod**, v. 10, n. 1, p. 1-9, 2022.
24. MASSACCI, F. R. et al. Characterization of *Pasteurella multocida* involved in rabbit infections. **Veterinary microbiology**, v. 213, p. 66-72, 2018.

25. MOHAMED, H. B.; ATTIA SHAFIE, M. A.; MEKKAWY, A. I. Chitosan nanoparticles for meloxicam ocular delivery: development, in vitro characterization, and in vivo evaluation in a rabbit eye model. **Pharmaceutics**, v. 14, n. 5, p. 893, 2022.
26. NABIEVA, N. BLOOD PATHOLOGY OF RABBITS IN PASTEURILLOSIS. **Science and innovation**, v. 2, n. D2, p. 38-40, 2023.
27. OKERMAN, L.; SPANOGHE, L.; DE BRUYCKER, R. M. Experimental infections of mice with *Pasteurella multocida* strains isolated from rabbits. **Journal of Comparative Pathology**, v. 89, n. 1, p. 51-55, 1979.
28. QIU, R. et al. Experimental pathogenicity and comparative genome analysis of high-and low-virulence strains of rabbit-origin *Pasteurella multocida*. **Comparative Immunology, Microbiology and Infectious Diseases**, v. 90, p. 101889, 2022.
29. RUDZIK, K. N. et al. Rabbit Anti-Thymocyte Globulin for Treatment of Corticosteroid Refractory Acute Cellular Rejection After Lung Transplantation. **The Journal of Heart and Lung Transplantation**, v. 41, n. 4, p. S423, 2022.
30. SÁNCHEZ-RÍOS, A. et al. Validation of a preclinical dry eye model in New Zealand white rabbits during and following topical instillation of 1% ophthalmic atropine sulfate. **Animal Models and Experimental Medicine**, v. 5, n. 3, p. 266-273, 2022.
31. SANTANA, C. P. et al. Corneal Permeability and Uptake of Twenty-Five Drugs: Species Comparison and Quantitative Structure–Permeability Relationships. **Pharmaceutics**, v. 15, n. 6, p. 1646, 2023.
32. SANTIANI, F. et al. Surto de Pasteurelose por *Pasteurella multocida* tipo A em coelhos (*Oryctolagus cuniculus*). **Acta Scientiae Veterinariae**, v. 47, n. 1, p. 413, 2019.
33. SHENG, Y. et al. N-acetylcysteine functionalized chitosan oligosaccharide-palmitic acid conjugate enhances ophthalmic delivery of flurbiprofen and its mechanisms. **Carbohydrate Polymers**, v. 291, p. 119552, 2022.
34. SPILKI, F. R. Um surto de pasteurelose em coelhos mantidos em biotério. **Acta Scientiae Veterinariae**, v. 30, n. 2, p. 131-134, 2002.
35. TANNER, K. et al. Corticosteroid-LABA inhalers increase phonation threshold pressure (PTP) and flow (PTF) in rabbits. **The Laryngoscope**, 2023.
36. UYAR, H. G. et al. Comparison of N-Acetyl Cysteine and Resveratrol Treatments in Acetaminophen Toxicity Model in Rabbits. **Ahi Evran Medical Journal**, v. 6, n. 3, p. 282-289, 2022.
37. VALENTIM, J. K. et al. Perfil dos criadores de coelho pet no Brasil. **Revista Brasileira de Cunicultura**, v. 13, n. 1, p. 27-45, 2018.
38. WANG, J. et al. Characterization of *Pasteurella multocida* isolated from dead rabbits with respiratory disease in Fujian, China. **BMC Veterinary Research**, v. 15, n. 1, p. 1-6, 2019.

39. WILSON, B. A.; HO, M. *Pasteurella multocida*: from zoonosis to cellular microbiology. **Clinical microbiology reviews**, v. 26, n. 3, p. 631-655, 2013.
40. ZHU, W. et al. Characterization of *Pasteurella multocida* isolates from rabbits in China. **Veterinary Microbiology**, v. 244, p. 108649, 2020.
41. ZHU, W. et al. Combinations but Not a Single PlpE Epitope Induces Host Protective Immunity against *Pasteurella multocida*. **Infection and Immunity**, v. 91, n. 3, p. e00272-22, 2023.